

## CASE STUDY

- 100% WOUND REDUCTION
- TOTAL HEALING IN 5 WEEKS
- 5 ACTIGRAFT APPLICATIONS

### PATIENT:

47 year-old, female.

### PAST MEDICAL HISTORY:

DM2, Hypothyroidism

### LABS:

HgB/HCT 11.2/35.7, MCV 77.6, MCH 24.3, Platelets 133

### WOUND HISTORY:

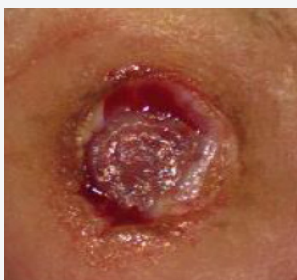- Diabetic Ulcer 2A, Plantar Aspect of Right Foot
- 10 Week Old Ulcer
- ABI Results for the Affected Leg = 1.15
- 1.3 cm<sup>2</sup> x 0.4 cm, Moderate Amounts of Serous/Sanguineous Drainage

### PAST TREATMENTS:

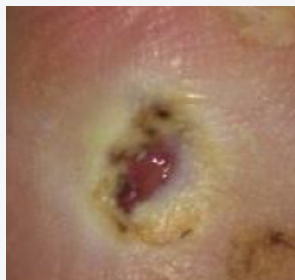Drawtex, Collagen and Regular Surgical Debridement

### ACTIGRAFT TREATMENT PROGRESSION:

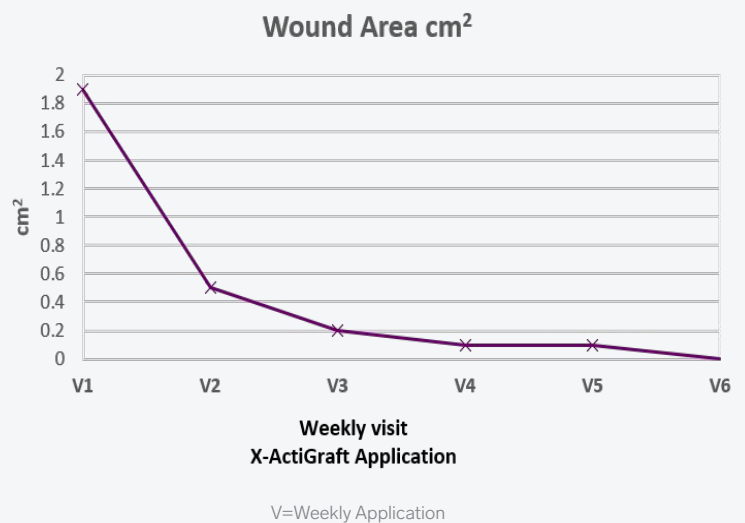
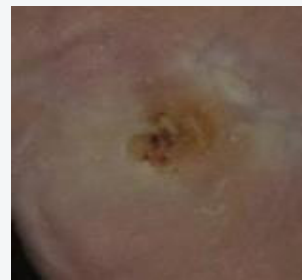Day 0



Day 14



Day 35



### OFFLOADING:

TCC